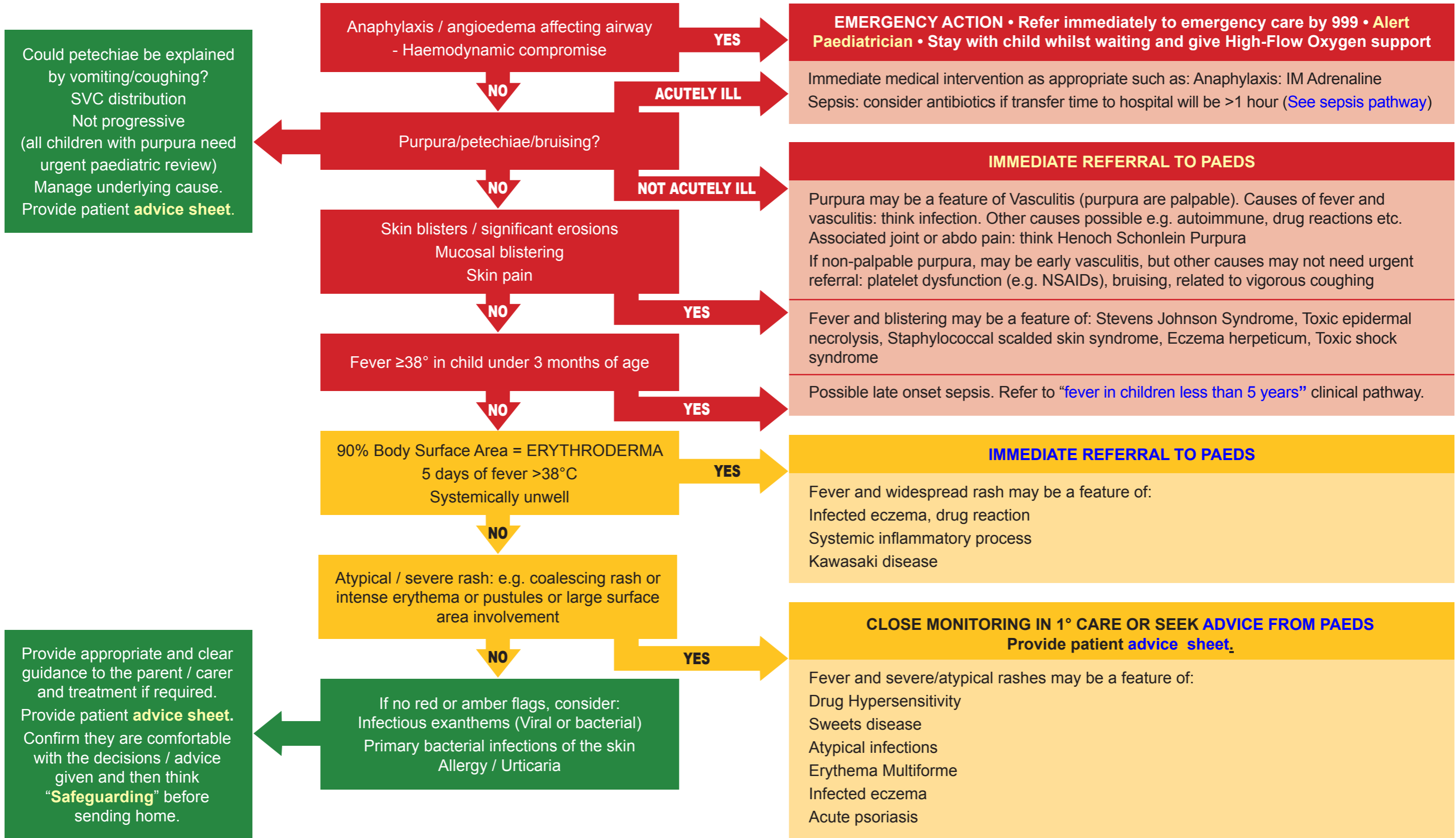


# Fever and Rash Pathway

Clinical Assessment/ Management tool for Children



## Management - Primary Care and Community Settings



GMC Best Practice recommends: Record your findings (See “Good Medical Practice” <http://bit.ly/1DPX12b>)

First Draft Version: November 2017 Review Date: November 2019.

# Fever and Rash Pathway

Clinical Assessment/ Management tool for Children



## Management - Primary Care and Community Settings

Differential Diagnosis	Distinguishing features
<b>Viral infections</b>	
Measles	Erythematous maculopapular rash over hairline/forehead and behind the ears, spreading caudally. Koplik spots (gray papules on buccal mucosa). Overwhelming misery. Obtain vaccine history.
Rubella	Eythematous maculopapular rash on face, spreads to extremities. Tender lymphadenopathy (occipital, postauricular, cervical)
Chicken pox	Consider bacterial secondary infection if fever 3 or more days after onset of chickenpox or increasing erythema around lesions. Consider toxic shock syndrome if haemodynamically unstable, generalised rash (erythroderma) and mucosal erythema (red eyes, red lips).
Eczema herpeticum	Disseminated viral infection (usually HSV1/HSV2) characterised by fever and clusters of itchy blisters or punched-out erosions. Severe eczema herpeticum may affect multiple organs. Risk of bacterial secondary infection (staph aureus or Gp A strep).
Other viral exanthems (enterovirus, adenovirus, HHV6, parvovirus, Coxsackie virus etc)	'Slapped cheek' (parvovirus B19 –also causes hydrops fetalis) - macular erythema over cheeks, lacy eruption on extremities; <b>Papular purpuric gloves and socks syndrome</b> (parvovirus B19) – erythema, oedema, petechiae/purpura on palms and soles with burning/pruritis; <b>Roseola</b> (HHV-6) – circular/elliptical macules/papules on trunk +/- surrounding white halo – rash as fever subsides; Herpangina (various enteroviruses) – exanthem (often absent), painful grey oral vesicles; <b>Hand-Foot-Mouth Disease</b> (Coxsackie A16>enterovirus 71) – grey vesicles, pustules and erosions on hands, feet and buttocks with oral vesicles/erosions on an erythematous base; <b>Infectious mononucleosis</b> (EBV) – morbilliform rash, pharyngitis, fatigue, myalgia, hepatosplenomegally, lymphadenopathy.
<b>Bacterial infections</b>	
Meningococcal disease	Short prodromal phase (fever, lethargy, malaise, nausea/vomiting), followed by the more specific and severe symptoms of meningitis and sepsis (limb pain, cold hands/feet, pale or mottled skin). Associated with non-blanching rash - a rapidly evolving petechial or purpuric rash is a sign of very severe disease.
Scarlet fever	Erythema of axilla, neck, chest, evolution to pink papules on erythematous background. Pastia's lines (linear petechial streaks in body folds). Red strawberry tongue. 7-10 days later hand and foot desquamation.
Cellulitis	Erythema, oedema and pain.
Impetigo	<b>Bullous</b> (only staph aureus) – flaccid see through bullae which rupture leaving a shiny dry erosion with an erythematous base +/- fever/diarrhoea/lethargy; <b>Non bullous</b> (S aureus >> Gp A strep) – eythematous macule – pustule/vesicle – erosion with golden crust – fever should be minimal.
Staph scalded skin syndrome	Fever, conjunctivitis, skin pain and flexural erythema with subsequent desquamation. NB culture of bullae negative.
Staph/strep toxic shock syndrome	Macular exanthem (on trunk spreading outwards), palmoplantar erythema and oedema with subsequent desquamation , conjunctival hyperaemia + hypotension + involvement of three or more organs. Risk factors include recent chickenpox and minor burns.
Secondarily infected eczema	Weeping, crusting or pain occurring on the background of eczema should prompt consideration of secondary bacterial infection.

# Fever and Rash Pathway

Clinical Assessment/ Management tool for Children



## Management - Primary Care and Community Settings

Differential Diagnosis	Distinguishing features
<b>Drug Reactions</b>	
<b>Severe</b> - <a href="#">Steven Johnson syndrome (SJS)</a> /toxic epidermal necrolysis (TEN)	Occurring after 7-21 after exposure to a new drug. Rash often preceded by prodromal illness (fever, sore throat, myalgia, conjunctivitis). Rash starts on trunk, extends to limbs (spares soles and palms). SJS < 10% BSA, widespread purpuric macules or atypical targets. TEN > 30% BSA +/- widespread purpuric macules. Mucosal involvement including eyes, mouth/lips, pharynx/oesophagus, genitalia, upper respiratory tract and GI tract. (SJS often occurs in response to infection in the absence of a precipitating drug. Mycoplasma pneumoniae is commonly implicated, often producing a more marked mucosal pattern of disease).
<a href="#">Drug Hypersensitivity (DRESS – Drug Rash with Eosinophilia and Systemic Symptoms)</a>	Occurring 7-40 days after exposure to new drug. Often morbilliform in appearance, worse initially over the face and upper body. Facial oedema is frequent. Atypical targetoid lesions, pustules, vesicles and purpura may occur. Fever, eosinophilia, lymphadenopathy, internal involvement organ (most frequently hepatitis – risk of liver failure).
Acute Generalised Exanthemous Pustulosis ( <a href="#">AGEP</a> )	Erythema and swelling with large numbers of overlying superficial pustules. Most commonly affecting the face and flexures initially. Occurs shortly after or within 4 days of exposure of a culprit drug (commonly antibiotics, but numerous drugs have been reported).
<b>Frequently non-infective causes</b>	
<a href="#">Sweet's Syndrome</a>	Erythematous tender nodules and plaques, often with associated pustules. Neutrophilia and fever. Occurring in response to underlying malignancy, upper respiratory tract infection, inflammatory bowel disease, rarely drug-induced.
<a href="#">Erythema multiforme</a>	Erythematous targetoid-lesion (bull's eye appearance). Minimal associated itch. Common over acral sites, but any part of the body may be affected. In some cases it can be associated with blistering and/or mucosal lesions. May be idiopathic, but Herpes Simplex Virus and mycoplasma pneumonia infection are commonly implicated.
<a href="#">Henoch Schonlein purpura (HSP)</a>	Classically presents with symmetrical palpable purpura on legs and buttocks in an otherwise well child. May involve joint pain/swelling, abdominal pain and haematuria. Most commonly occurs in children aged 2-11 years. Monitor BP and urine (for blood and protein)
Kawasaki disease	Fever >5 days, <a href="#">rash</a> , bilateral non-exudative <a href="#">conjunctivitis</a> , <a href="#">oral signs</a> (red, cracked lips), oedema of <a href="#">hands/feet</a> and cervical LAN (>1.5cm). <a href="#">Overwhelming misery extremely common</a> . Signs may appear and disappear before others arise. 80% of cases occur in children <5 years of age (peak incidence 1 to 2 years).